

Success of surgical interventions for direct dental implant-related injuries to the mandibular nerve: a review

L.M. Fee*

BA BDS, MSc in Dental Implants(Bristol University), Diploma in Primary Care Oral Surgery, RCS(Eng), Diploma in Conscious Sedation (Newcastle University), Cert in Clinical Education (Edinburgh University)

Available online 12 May 2020

Abstract

To the best of our knowledge there are no guidelines regarding the surgical management of dental implant-related injuries to the mandibular nerve. This review aims to investigate the success of different surgical interventions. Neurosensory injury to the mandibular branch of the trigeminal nerve can occur during administration of local anaesthetic, elevation of the flap, preparation for osteotomy, and placement of the implant. Surgical interventions include extraction of the implant, external decompression, internal neurolysis, excision of a neuroma, neuroorrhaphy, nerve grafting, and low-level laser therapy. The following electronic databases were searched: MEDLINE, EMBASE, and the Cochrane Library. Primary outcome measures included patient-reported outcomes such as pain and altered sensation. A total of 185 publications were obtained, of which 21 were included in the qualitative synthesis (2 randomised controlled trials (RCT), 9 controlled cohort studies, and 10 case reports/series). They were all screened in consideration of the exclusion criteria and appraised using the Cochrane risk of bias tool, the Newcastle Ottawa scale, and the modified Newcastle Ottawa scale. Results were triangulated to evaluate their level of agreement. The extraction of dental implants less than 36 hours after injury to the mandibular nerve results in the most successful resolution of neurosensory dysfunction. Various microsurgical techniques have shown less success in obtaining neurosensory recovery than extraction of the implant. However, microsurgery is worthwhile, as it improves neurosensory dysfunction and reduces dysaesthesia in the majority of patients. Direct suturing and external decompression can result in good neurosensory recovery, and nerve grafts are also successful whenever tension-free direct suturing is not possible. Low-level laser therapy has been shown to achieve some neurosensory improvement.

© 2020 Published by Elsevier Ltd on behalf of The British Association of Oral and Maxillofacial Surgeons.

Introduction

Guidelines relating to the surgical management of mandibular nerve injuries that relate directly to dental implants are lacking. Neurosensory injury to the nerve can happen at every step, such as during the administration of local anaesthetic, elevation of the flap, preparation for osteotomy, and placement.¹ The morbidity and psychological distress that such injuries cause make it vital to establish the effects of the available surgical interventions.²

Currently there is no consensus regarding optimum surgical management.³ Many studies have different final assessment measures, which makes comparison difficult.^{4–6}

This review aims to investigate the success of the surgical interventions that aim to resolve neurosensory disturbances that arise from mandibular nerve injuries that are directly related to dental implants.

Surgical procedures for dental implant-related injuries

Nerve exploration

Cone-beam computed tomography (CBCT) helps to locate the inferior alveolar canal (IAC), and magnetic resonance imaging (MRI) can aid visualisation of the lingual (LN) or mandibular nerve (MN). However, the best view of an IAN injury is gained through surgical exploration. This helps to find out whether the dental implant is in contact with the nerve or whether bony fragments or foreign bodies, such as

* Address: 22 The Crescent, Clontarf, Dublin 3

graft materials, are impinging on it. It also confirms whether or not scar tissue is associated.⁷

Removal of dental implants

If an IAN injury is seen during the placement of implants, it is essential that the implant is removed within 36 hours. If fully osseointegrated then a trephine burr is needed to cut circumferentially around it to facilitate removal. Reverse torque kits help to limit the amount of bone removed. Care is needed to avoid pressing bone graft material on to the exposed nerve. Immediate placement of a wider and shorter dental implant is an option, but removal of an implant after osseointegration is unlikely to resolve the nerve damage.²

Excision of neuroma

Following injury to the mandibular nerve by a dental implant, disorganised axonal regeneration can lead to the formation of a neuroma. These injuries arise from sectioning, crushing, stretching, and laceration of the nerve. Direct injury from a drill or contact of an implant with the IAN can also cause a neuroma to form and result in dysaesthesia. Partial transection of the nerve usually heals with the formation of a scar and misconduction of neuronal tissue. After a neuroma has been removed, nerve grafts are often needed to restore the continuity of the defect.³

External or internal neurolysis

Collapse of the IAC due to impingement by the implant or grafting material can cause compression of the IAN. External neurolysis is where the nerve is released from its connective tissue bed and fibrotic tissue is removed. Injury to the nerve may cause scar tissue to form, which constricts the nerve, blocks transmission, and prevents neuronal recovery. External neurolysis involves the removal of bone and soft tissue surrounding the nerve, and repositioning of the nerve is an option whenever it is compressed by an implant.⁴

Internal neurolysis, which is a technique that involves releasing the neuronal fascicles from epineural fibrosis, is indicated in the presence of fibrosis, but it risks the formation of more scar tissue. Internal neurolysis involves opening the epineurium and inspecting its internal structure to find out whether the decompression of individual neural fascicles is needed. If a continuity defect of these fascicles exists, then neuroorrhaphy or nerve grafting is necessary for neuronal reconstruction. If the nerve is intact, external decompression and internal neurolysis are adequate. Internal neurolysis requires great precision, as it risks appreciable scar formation and further damage to the fascicles.⁵

Neuroorrhaphy

This technique is also known as direct anastomosis or suturing. It is indicated when a nerve is transected and both its ends can be sutured together without tension. Normally, defects of less than 1 mm can be repaired directly with epineural sutures, and this is the method of choice for repair of a witnessed nerve transection (Fig. 1).⁶

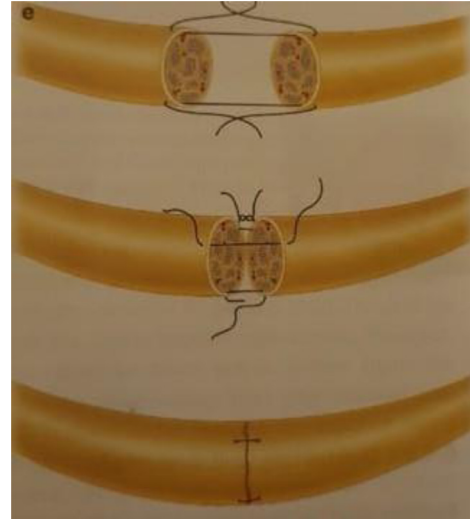


Fig. 1. Neuroorrhaphy procedure²⁹.

It is easier to repair the LN with direct neuroorrhaphy than it is to repair the IAN, as tension-free mobilisation and approximation of the IAN are difficult. Transecting the incised nerve can help to mobilise it, but there is a resultant loss of sensation involving the lower anterior teeth and labial gingiva.⁸

Nerve grafting

Successful neuroorrhaphy involves approximating the transected IAN in a tension-free manner. However, when this is not possible an interpositional nerve graft may be used. The most commonly used autogenous grafts are the sural nerve (SN) and greater auricular nerve (GAN). The SN is more similar in size to the trigeminal nerve and is longer than the GAN, but SN grafts have a distant donor site and leave an ankle scar. The GAN is easily harvested along the sternocleidomastoid muscle 6 cm inferior to the ear lobe. The incision is usually hidden within the natural crease of the neck, and the loss of sensation in this area is rarely a problem. Multiple strands of the GAN can be used if its diameter is too small.⁹

Low-level laser therapy

Laser treatment before and after surgical interventions can increase the speed of recovery of a mandibular nerve injury and reduce neurosensory disturbances.¹

Results

Studies on the extraction of dental implants (Table 1)^{2,10–17}

Bhavsar et al reported a patient with a residual burning sensation that was measured on a visual analogue scale (VAS) as 1/10. After 12 months the numbness around the lips was 10%

Table 1
Studies on the extraction of dental implants.

First author, year, and reference	Time from injury to repair	No. of patients	Mean age (years)	Duration of follow up	Operation	Success rate
Bhavsar 2015 ¹⁰	24 hours	1	45	1 year	Dental implant extracted	Almost complete resolution of altered sensation
Elian 2005 ¹¹	50 months	1	34	1 year	Dental implant extracted	Paraesthesia resolved
Givol 2013 ¹²	2 patients treated <12 hours post-injury 7 patients treated <24 hours 4 patients treated <48 hours 10 patients treated < 1 week 27 patients treated between 1 week and 12 months	92	58	1 year	Dental implant extracted	No symptoms resolved
Juodzbaly 2013 ¹³	8 cases treated <36 hours	16	52	6 months	Dental implant extracted	8 cases completely healed
Khawaja 2009 ²	Case 1: 18 hours post-injury Case 2: 36 hours Case 3: 2 days Case 4: 4 days	4	49	3 months	Dental implant extracted	Cases 1 and 2 achieved almost complete sensory recovery. Cases 3 and 4 did not experience any improvement
Leckel 2009 ¹⁴	5 months	1	56	1 year	Dental implant extracted	Complete neurosensory resolution
Park 2012 ¹⁵	4 weeks – 9 months	2	56	4 months	Dental implant extracted	Complete neurosensory resolution
Renton 2012 ¹⁶	30 hours - 6 months	13	50.6	3 years	Dental implant extracted	No neurosensory resolution
Sahl 2018 ¹⁷	3 months	1	58	1 year	Dental implant extracted	Complete neurosensory resolution

of its original size.¹⁰ Elian et al reported a considerable reduction in paraesthesia after removal of an implant 50 months after insertion.¹¹ Clinical mapping and evaluation showed a 40% improvement at three months and a 60% functional sensory recovery (FSR) at six months. The patient reported a slower rate of FSR after six months.¹¹ Givol et al showed no resolution of symptoms in any of the patients.¹² In this study seven patients had dental implants removed after less than 24 hours, and four after less than 48 hours. All other implants were removed more than 48 hours later.¹² Juodzbaly et al reported that eight patients had their dental implants removed less than 36 hours after insertion.¹³ Four cases of altered sensation were attributed to damage from drilling to prepare for placement, and three to nerve damage that was not related to preparation or placement of the implant. Results indicated that eight patients healed completely, seven had persistent moderate sensory alteration, and one continued to experience severe neurosensory disturbances.¹³ Khawaja and Renton showed that Cases 1 and 2 had their implants extracted within 18–36 hours after placement, and had complete resolution of symptoms. However, Cases 3 and 4 had their implants removed two and four days postoperatively and both patients had persistent neuropathies.² Leckel et al found that pain gradually disappeared over 12 months after the dental implant was removed.¹⁴ Park et al reported that removal of the implant resulted in the relief of hypaesthesia and paraesthesia in Case 1, and complete resolution of paraesthesia in Case 2.¹⁵ Renton et al showed that in three patients who were referred within 30 hours, symptoms of neuropathy

resolved over several weeks after their dental implants were removed. In 10 patients there was no resolution of neuropathy after implants had been extracted between three days and six months postoperatively.¹⁶ Sahl et al showed that the partial extraction of an implant that had breached the IAC avoided possible injury to a fully recovered IAN.¹⁷

Studies that reported the use of various microsurgical techniques (Table 2)^{3,18–26}

Bagheri et al showed that surgical interventions for IAN injuries resulted in an acceptable improvement in 81.7% of participants.³ The success rate for direct suturing was 88.9% and for external decompression was 85%. Autogenous nerve grafting resulted in an 87.3% success rate. Gregg showed that despite surgery, constant daily discomfort in the lip and chin persisted in Case 1.¹⁸ Surgical decompression resulted in partial FSR in Case 2, but paraesthesia and “burning” pain persisted. Lam et al showed that satisfaction was good in 55% of patients, fair in 28%, and poor in 17%.¹⁹ Direct suture repair was completed in 70% of patients and 67% had neuromas present. Pogrel reported that 26 patients had excision and direct anastomosis, and 20 had nerve-gap reconstructions.²⁰ Results showed that 10 patients had good neurosensory improvement, 18 had some improvement, and 22 had no change in symptoms. One patient reported increased neurosensory dysfunction postoperatively.

Strauss et al reported that all patients required external neurolysis, that 39.3% also had internal neurolysis,

Table 2

Studies that reported the use of various microsurgical techniques (external decompression, internal neurolysis, neuroma excision and neuroorrhaphy).

First author, year, and reference	Time from injury to repair	No. of patients	Mean age (years)	Duration of follow up	Operation	Success rate
Bagheri 2012 ³	10.7 months	167	38.7	1 year	10.8% external decompression 32.3% internal neurolysis 9% neuroma excised 9.7% neuroorrhaphy 38.2% autogenous nerve graft	81.7% of patients achieved an acceptable level of neurosensory function
Gregg 2000 ¹⁸	Case 1: 3 months Case 2: 1 year	2	47.5	1 year	Case 1: neuroma resected and graft inserted Case 2: surgical decompression	Case 1: constant daily discomfort persisted Case 2: paraesthesia and “burning” pain remained
Lam 2003 ¹⁹	6.8 months	46	28	1 year	Direct suture repair Neuroma excised Nerve graft	55% reported their surgical outcomes as excellent or good
Pogrel 2002 ²⁰	4.5 months	51	No data	No data	5 patients had decompression 26 patients had excision and direct anastomosis 20 patients had nerve gap reconstruction (2 patients had autogenous vein grafts)	50% of patients experienced neurosensory improvement
Strauss 2006 ²¹	6.6 months	32	38.5	9.5 months	External/internal neurolysis Neuroorrhaphy Excision of a neuroma	53.6% experienced mild improvement 35.7% experienced significant improvement 10.7% reported no improvement
Susarla 2005 ²²	4.5 months	19	25.8	1 year	Neuromas excised in 78.9% of patients 70% of nerve defects repaired by direct suturing	84.2% experienced some improvement 10.5% experienced no change 1 patient had a lower neurosensory score than preoperatively
Robinson 2008 ²³	28 months	25	40	1 year	IAN decompression and neurolysis	All patients achieved a 20% improvement in neurosensory status
Susarla 2007 ²⁴	21.9% of patients were treated <90 days Late repair was considered > 90 days	64	28	1 year	77% repaired with direct suture 23% had surgical exploration with decompression/neurolysis	93% of patients achieved full recovery after early surgical repair Complete recovery in 62.9% of patients in the late repair group
Kim 2011 ²⁵	No data	3	No data	No data	End-to-end repair of IAN defects using the nerve sliding method	No FSR data provided but no neurological problems from transection
Miloro 2005 ²⁶	No data	26	32	20 months	Sural nerve grafting completed	All cases had successful outcomes

and 42.9% direct suture repair.²¹ The results indicated that improvement was mild in 53.6% of patients, substantial in 35.7%, and there was no improvement in 10.7%. Susarla et al reported that 84.2% of patients experienced neurosensory improvement; there was no change in 10.5%, and one patient had a lower neurosensory score postoperatively.²² Neuromas were found in 78.9% of operations and nerve defects were repaired by direct suturing in 70% of patients.²² Robinson et al conducted a study in which delayed surgical interventions generally occurred at 28 months. There was typically a 20% improvement after microsurgical interventions.²³ The IAN surgery resulted in a considerable reduction

in pain, but the overall level of improvement was not significant.

Susarla et al showed that 93% of patients in the early repair cohort achieved complete FSR compared with 62.9% in the late cohort.²⁴ In the successful early repair (less than 90 days) group 85.7% of patients had direct suture repair. Only 6/14 patients in the early group compared with 37/50 in the late group had neuromas excised.

Nerve grafting (Table 2)^{25,26}

Kim et al reported three nerve repairs using the “nerve-sliding technique” for gaps of 10 mm and there were no neurosen-

Table 3
Low-level laser treatment studies.

First author, year, and reference	Time from injury to repair	No. of patients	Mean age (years)	Duration of follow up	Intervention	Success rate
Khullar 1996 ²⁷	No data	13	38	2 years	Low-level laser treatment	Some significant improvement
Khullar 1996 ²⁸	No data	18	38	6 months	Low-level laser treatment	No improvement

sory disturbances after incisive nerve grafting.²⁵ Miloro and Stoner reported the results of a questionnaire regarding the success of SN grafting, and all patients were satisfied with the level of FSR achieved.²⁶

Low-level laser therapy (Table 3)^{27,28}

Khullar et al reported some evidence of FSR measured by VAS scores within the laser group.²⁷ In another paper they showed a subjective improvement in FSR in the laser group.²⁸ However, data were missing regarding this outcome in Methods and Results. The number of patients was small and the evidence included only those with partial neurosensory loss.

Discussion

Four studies that involved the extraction of dental implants after injury to the mandibular nerve included patients who achieved complete FSR.^{14,15,17,18} Early removal less than 36 hours after placement resulted in the most success.^{2,11,15} Some studies reported that removal after more than 36 hours did not result in successful FSR.^{2,12,16} Overall, in the nine studies on the extraction of dental implants that included 131 patients, complete FSR was achieved in 20 (15.3%).^{2,10–17} Permanent neurosensory dysfunction persisted in 111 (84.7%).

Some studies on the late extraction of implants, however, reported successful FSR. Sahl et al described complete FSR after the removal of implants at two months.¹⁷ Similarly Park et al reported complete FSR after two extractions of dental implants at four weeks and nine months.¹⁵ Leckel et al also reported the disappearance of neurosensory dysfunction when dental implants were extracted five months after placement.¹⁴

Only one study on microsurgical techniques reported that participants (68.7%) achieved complete FSR.²⁵ Overall, the remaining studies reported acceptable levels of improvement in FSR in 69% of patients. Papers that involved direct suturing reported the most success in terms of FSR.^{3,20–22,26}

Studies that involved microsurgical techniques showed less success in obtaining complete FSR than those that involved the extraction of dental implants. Within the microsurgical studies the technique that resulted most successfully in some neurosensory improvement was direct suturing.^{3,20–23,25} External decompression also resulted in worthwhile improvements in FSR,^{3,21,22,24,25} as did nerve

grafting techniques.^{3,21,23,25,27} However, low-level laser therapy resulted in only some improvement.^{12,28}

Overall, a large number of patients in 15/21 studies continued to experience permanent neurosensory disturbances after surgical interventions.^{2,3,11,13,14,16,19–26,28} Four studies that involved extractions of dental implants,^{12,15,17,18} one that exclusively evaluated nerve grafting,²⁶ and one that assessed various microsurgical interventions²⁵ reported patients who achieved complete FSR. Overall, surgical interventions had a low and unpredictable level of success in achieving complete FSR after mandibular nerve injuries directly related to dental implants.

Conclusions

The early removal of dental implants less than 36 hours after injury to the mandibular nerve achieved complete FSR most successfully. Late extraction of implants had a lower success rate in terms of FSR, but is still a worthwhile treatment. Microsurgical techniques were less successful in obtaining FSR than the extraction of implants, but microsurgery is still worthwhile, as it improved neurosensory dysfunction and reduced dysaesthesia in most patients. Direct suturing had the best outcome, and external decompression also resulted in good neurosensory improvement. If excision of a neuroma is necessary with direct suturing, a reduced level of FSR can be achieved. Nerve grafting had good success rates whenever tension-free direct suturing was not possible, and low-level laser therapy resulted in some improvement in FSR.

Overall, surgical interventions had low levels of success in achieving complete FSR in these cases with large numbers of participants continuing to report permanent neurosensory disturbances. A short duration of time between the injury and repair increased the likelihood of complete FSR. There was a reduced chance of surgical interventions achieving complete FSR in cases that involved severe mandibular nerve injuries and in patients who reported painful preoperative symptoms, but increased age did not affect success.

Ethics statement/confirmation of patients' permission

No ethics approval required. No patients' permission required.

Conflict of interest

I have no conflicts of interest.

References

- Coulthard P, Kushnerev E, Yates JM, et al. Interventions for iatrogenic inferior alveolar and lingual nerve injury. *Cochrane Database Syst Rev* 2014;**4**:CD005293.
- Khawaja N, Renton T. Case studies on implant removal influencing the resolution of inferior alveolar nerve injury. *Br Dent J* 2009;**206**:365–70.
- Bagheri SC, Meyer RA, Cho SH, et al. Microsurgical repair of the inferior alveolar nerve: success rate and factors that adversely affect outcome. *J Oral Maxillofac Surg* 2012;**70**:1978–90.
- Greenwood M, Corbett IP. Observations on the exploration and external neurolysis of injured inferior alveolar nerves. *Int J Oral Maxillofac Surg* 2005;**34**:252–6.
- Ziccardi VB, Steinberg MJ. Timing of trigeminal nerve microsurgery: a review of the literature. *J Oral Maxillofac Surg* 2007;**65**:1341–5.
- Tay AB, Poon CY, Tey LY. Immediate repair of transected inferior alveolar nerves in sagittal split osteotomies. *J Oral Maxillofac Surg* 2008;**66**:2476–81.
- Hegedus F, Diecidue RJ. Trigeminal nerve injuries after mandibular implant placement – practical knowledge for clinicians. *Int J Oral Maxillofac Implants* 2006;**21**:111–6.
- Kraut RA, Chahal O. Management of patients with trigeminal nerve injuries after mandibular implant placement. *J Am Dent Assoc* 2002;**133**:1351–4.
- Wolford LM, Rodrigues DB. Autogenous grafts/allografts/conduits for bridging peripheral trigeminal nerve gaps. *Atlas Oral Maxillofac Surg Clin North Am* 2011;**19**:91–107.
- Bhavsar I, Khalaf M, Ferrin J, et al. Resolution of implant-induced neurosensory disturbance: a procedural failure. *Implant Dent* 2015;**24**:735–41.
- Elian N, Mitsias M, Eskow R, et al. Unexpected return of sensation following 4.5 years of paraesthesia: case report. *Implant Dent* 2005;**14**:364–7.
- Givol N, Peleg O, Yarom N, et al. Inferior alveolar neurosensory deficiency associated with placement of dental implants. *J Periodontol* 2013;**84**:495–501.
- Juodzbaly G, Wang HL, Sabalys G, et al. Inferior alveolar nerve injury associated with implant surgery. *Clin Oral Implants Res* 2013;**24**:183–90.
- Leckel M, Kress B, Schmitter M. Neuropathic pain resulting from implant placement: case report and diagnostic conclusions. *J Oral Rehabil* 2009;**36**, 543–6.26.
- Park YT, Kim SG, Moon SY. Indirect compressive injury to the inferior alveolar nerve caused by dental implant placement. *J Oral Maxillofac Surg* 2012;**70**:e258–9.
- Renton T, Dawood A, Shah A, et al. Post-implant neuropathy of the trigeminal nerve. A case series. *Br Dent J* 2012;**212**:E17.
- Sahl E, Alqahtani A, Alqahtani NM, et al. Partial explantation of failed dental implants placed in mandibular canal: a case report. *J Oral Implantol* 2018;**44**:456–61.
- Gregg JM. Neuropathic complications of mandibular implant surgery: review and case presentations. *Ann R Australas Coll Dent Surg* 2000;**15**:176–80.
- Lam NP, Donoff RB, Kaban LB, et al. Patient satisfaction after trigeminal nerve repair. *Oral Surg Oral Med Oral Pathol Oral Radiol Endod* 2003;**95**:538–43.
- Pogrel MA. The results of microneurosurgery of the inferior alveolar and lingual nerve. *J Oral Maxillofac Surg* 2002;**60**:485–9.
- Strauss ER, Ziccardi VB, Janal MN. Outcome assessment of inferior alveolar nerve microsurgery: a retrospective review. *J Oral Maxillofac Surg* 2006;**64**:1767–70.
- Susarla SM, Lam NP, Donoff RB, et al. A comparison of patient satisfaction and objective assessment of neurosensory function after trigeminal nerve repair. *J Oral Maxillofac Surg* 2005;**63**:1138–44.
- Robinson PP, Yates JM, Smith KG. A prospective, quantitative study on the clinical outcome of inferior alveolar nerve decompression and neurolysis. *Oral Surgery* 2008;**1**:35–44.
- Susarla SM, Kaban LB, Donoff RB, et al. Functional sensory recovery after trigeminal nerve repair. *J Oral Maxillofac Surg* 2007;**65**:60–5.
- Kim JH, Kim SM, Jung HJ, et al. Effective end-to-end repair of the inferior alveolar nerve defect by using nerve sliding technique. *Oral Surg Oral Med Oral Pathol Oral Radiol Endod* 2011;**112**:e28–30.
- Miloro M, Stoner JA. Subjective outcomes following sural nerve harvest. *J Oral Maxillofac Surg* 2005;**63**:1150–4.
- Khullar SM, Brodin P, Barkvoll P, et al. Preliminary study of low-level laser for treatment of long-standing sensory aberrations in the inferior alveolar nerve. *Journal of Oral and Maxillofacial Surgery* 1996;**54**:2–7.
- Khullar SM, Emami B, Westermark A, et al. Effect of low-level laser treatment on neurosensory deficits subsequent to sagittal split ramus osteotomy. *Oral Surg Oral Med Oral Pathol Oral Radiol Endod* 1996;**82**:132–8.